ISSN 2965-0771

Revista Brasileira de CANNABIS

SOCIEDADE BRASILEIRA DE ESTUDOS DA CANNABIS

DOI: 10.58731/2965-0771.2023.23

# EFFICACY OF TETRAHYDROCANNABINOL-RICH CANNABIS OINTMENT IN A CHILD WITH RECCESSIVE DYSTROPHIC EPIDERMOLYSIS BULLOSA: CASE REPORT

## EFICÁCIA DA POMADA DE CANNABIS RICA EM TETRAHIDROCANABINOL EM CRIANÇA COM EPIDERMÓLISE BOLHOSA DISTRÓFICA RECESSIVA RELATO DE CASO

Igor Bronzeado Cahino Moura de Almeida[1]; Patrícia de Gusmão Sampaio[1]; Renata da Silveira Rodrigues Paiva[2]; Daniela Karina Antão Marques[2]; Mariama Trigueiro Maia[2]; Laise O. Lucena[3]; Katy Lísias Gondim Dias de Albuquerque[4*]

*[1] Federal University of Paraíba, Brazil*

*[2] Lauro Wanderley University Hospital of the Federal University of Paraíba, Brazil*

*[3] Dom Luiz Gonzaga Fernandes Emergency and Trauma Hospital, Brazil*

*[4]Pharmacology Laboratory of Federal University of Paraíba, Clinical Research Center of Lauro Wanderley University Hospital and Member of Brazilian Society of Cannabis Studies, São Paulo, Brazil*

*Corresponding author: Clinical Research Center of Lauro Wanderley Hospital of Federal University of Paraíba. Postal code: 5009, Campus I, 58051-900, João Pessoa, PB, Brazil. E-mail address: katy_lisias@yahoo.com.br. Tel. +55 83 3216-7245.

*Submetido em 12 de julho de 2023*

*Aceito para publicação em 30 de novembro de 2023*

*Publicado em 09 de janeiro de 2024*

ISSN 2965-0771
Revista Brasileira de CANNABIS
SBEC SOCIEDADE BRASILEIRA DE ESTUDOS DA CANNABIS

**ABSTRACT**

**INTRODUCTION:** epidermolysis Bullosa (EB) is characterized by epithelial fragility with blistering and the presence of pain and chronic pruritus. Studies demonstrate the potential of cannabinoids in the treatment of dermatological disorders, presenting anti-inflammatory action, pruritus control, and analgesic effect. In addition, two case series of patients with EB demonstrated positive results with both topical and systemic use of cannabinoids. **OBJECTIVES:** to evaluate the therapeutic efficacy of the topical use of a tetrahydrocannabinol-rich (THC) *Cannabis sativa* ointment in a patient with EB. **METHODS:** this is the case report of a 4-year-old female patient with recessive dystrophic EB. Two similar chronic wounds were chosen, in which one was treated with the placebo and the other treated with the THC-rich Cannabis ointment. The influence on healing and on pain and pruritus symptoms was evaluated for 28 days. After this period, the blinding status was removed and, due to the results achieved, it was decided to continue the application of the THC-rich Cannabis ointment in both lesions. **RESULTS:** The THC-rich *Cannabis sativa* ointment improved the wound healing process and the control of pain and pruritus when compared to placebo. **CONCLUSIONS:** The use of the THC-rich Cannabis ointment was effective in the healing process of the chronic wounds presented by the patient. A positive effect was also observed in relation to pain, pruritus, and improvement in the overall quality of life.

**KEYWORDS:** Epidermolysis bullosa. Cannabis. Tetrahydrocannabinol. THC. Case report.

## INTRODUCTION

Epidermolysis Bullosa (EB) is a heterogeneous group of genodermatoses whose main characteristic is the marked epithelial fragility characterized by the formation of blisters at minimal trauma. EB is a rare disease, with an estimated incidence of 20 per 1,000,000 live births.[1]EB presents a great clinical variability depending on the skin layer where blister cleavage occurs and whether or not there is extracutaneous involvement. Blisters can be formed at basically three levels, namely: intraepidermal, junctional, and dermolytic. In the junctional form, blisters are formed between the epidermis and the dermis, while being formed below the dermis in the dermolytic. In the latter, lesions are usually more intense than in other cases.[2]

Thus, we can classify EB into four main types, namely: (1) epidermolysis bullosa simplex, in which the formation of blisters occurs intraepidermally, making them superficial, without leaving scars in most cases; (2) junctional epidermolysis bullosa, in which blisters are deeper and affect most of the body surface, being the most severe form. Death can occur before the first year of life; (3) dystrophic epidermolysis bullosa, in which blisters form even deeper below the basement membrane, which leads

to scarring and frequently loss of limb function; (4) Kindler EB, which was described more recently and presents a mixed picture, with blisters being formed at any level of the dermo-epidermal junction.[3,4]

Dystrophic EB is one of the most serious groups of genodermatoses, as besides epithelial fragility, with the appearance of blisters and secondary lesions such as erosions, ulcerations, crusts, and scars, patients also suffer from intense and unpleasant chronic pain in the skin, intense and refractory pruritus, and generalized skin inflammation.[5] In one study, the pain was even more severe than that of postherpetic neuralgia and the pruritus resembled that of patients with atopic dermatitis and chronic urticaria.[6]

Finally, in addition to injuries and secondary symptoms, patients still have psychological impairment, due to the stigma of injuries in society's view, and a high economic burden, especially due to expenses with the preparation of high-cost healing materials. Thus, the quality of life of these people is drastically affected. According to a study using the Skindex-29 score, which measures the interference of dermatological disorders in the patient's quality of life on a scale from 0 to 100, with 100 being the worst possible interference, patients with psoriasis obtained an average score of 34.6, while patients with dystrophic epidermolysis bullosa obtained an average score of 79.3.[5,6,7]

Essentially, the treatment of EB is precarious, with no cure or specific and effective therapies for the control of secondary lesions and symptoms. Patients need to be followed up by a multidisciplinary team that focuses mainly on wound management, treatment of pain and pruritus, and nutritional monitoring.[2,8]

However, more recent studies have demonstrated a great therapeutic potential of substances such as cannabidiol (CBD) and Delta-9-tetrahydrocannabinol (THC), which are the main active substances present in the *Cannabis sativa* plant for the treatment of chronic inflammatory skin disorders.[9,10]

Given these facts and the lack of specific therapy in EB, studies using products based on Cannabis sativa are being carried out in patients with EB. A series of three cases demonstrated beneficial effects of the topical use of isolated CBD extracts in patients with epidermolysis bullosa, resulting in reduced pruritus and especially chronic pain, skin inflammation, the number of blisters, and skin recovery time after emergence of new lesions. In addition, two out of the three patients were able to discontinue the use

of oral analgesics after starting treatment. Another important finding in this study was that two out of the three patients who had painful plantar hyperkeratosis improved their walking conditions throughout treatment.[5] In another case series, three EB patients who made sublingual use of oils containing different proportions of phytocannabinoids reported substantial improvement in the pruritus and pain sensation. In addition, two out of the three patients were able to wean off part of the drug therapy that was used for analgesia.[11]

In this context, the topical use of medicines based on the *Cannabis sativa* plant can become a promising alternative for the treatment of epidermolysis bullosa. Therefore, the main objective of this case report was to evaluate the effectiveness of the topical use of the THC-rich *Cannabis sativa* extract in the form of an ointment in a patient with EB.

## METHODS

This clinical study, which was described in the form of a case report, was carried out at the Dermatology outpatient clinic of the Lauro Wanderley University Hospital, located on CAMPUS I of the Federal University of Paraíba, being duly approved by the Ethics and Research Committee of the Health Sciences Center of the Federal University of Paraíba CAAE number: 31565020.0.0000.5188. The child's parents signed the Free, Prior, and Informed Consent in order for the child to participate in this study.

The 3% THC-rich *Cannabis sativa* ointment used in this study presented a THC concentration of 21.8 mg and a CBD concentration of 0.62 mg per gram after high-performance liquid chromatography analysis. The placebo and the 3% THC-rich *Cannabis sativa* ointment were donated by the ABRACE (*Associação Brasileira de Apoio Cannabis Esperança*), being distributed in identical vials containing only a numerical code on their label. The student who carried out the randomization was the only non-blind participant in the study, being the only one who knew how to decipher which code corresponded to the placebo and which code corresponded to the 3% THC-rich *Cannabis sativa* ointment, making this a double-blind study.

The patient who participated in this study was a 4-year-old female diagnosed with recessive dystrophic epidermolysis bullosa by genetic testing. At the first visit, she

exhibited large and widespread lesions throughout her body associated with severe pain and chronic pruritus.

In the first evaluation by the multidisciplinary team, two lesions of the patient with similar characteristics were evaluated and photographed. One of these lesions was called target lesion A and the other target lesion B. Both lesions were chronic and had appeared more than two years prior to the experiment. In addition, chronic pruritus and severe pain were reported for both lesions, especially during bathing and during daily dressing changes.

Target lesion A was an ulcerated lesion measuring approximately 8 cm in its greatest diameter, consisting of an erythematous-violaceous plaque in the anterior chest region. Target lesion B was an ulcerated lesion measuring approximately 6 cm in its largest diameter, consisting of an erythematous-violaceous plaque in the right trapezius (Figure 1).

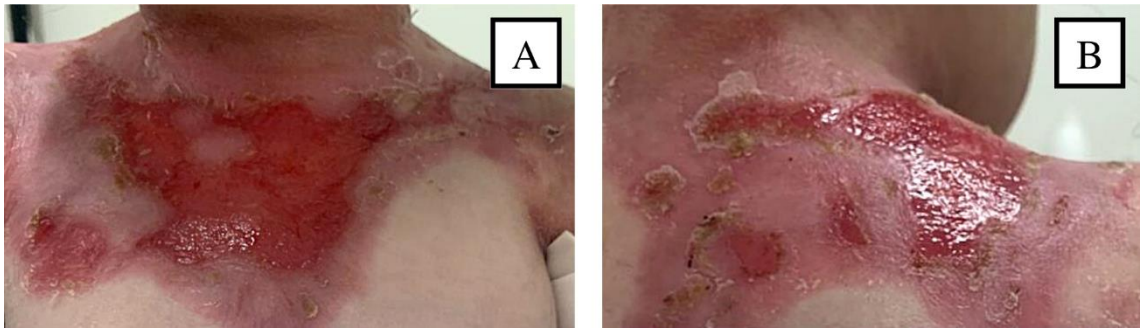


**Figure - 1** Target lesions on day zero (D0). (A) Target lesion A - ulcerated lesion consisting of an erythematous-violaceous plaque in the anterior chest region and (B) Target lesion B - ulcerated lesion consisting of an erythematous-violaceous plaque in the right trapezius region.

On the initial day of treatment, the vials were randomly selected and Target Lesion A received the vial containing the placebo, while target lesion B received the vial containing the 3% THC-rich Cannabis ointment. For 28 days, a thin layer of placebo and ointment was applied to the surface of the respective lesions, followed by the use of the dressing that was already used on both lesions. At the end of the 28th day, the blinding of the products was removed.

In addition to the weekly follow-up consultations with the evaluation of the lesions and the capturing of photographs, the patient and her family received a diary to measure the pain and pruritus associated with Target Lesions A and B and any other noticeable changes in other aspects of the patient's life daily on a visual analogue scale.

It is important to note that neither the ointment nor the placebo promoted any worsening of the skin of the patient in this study.

**RESULTS**

Regarding the appearance of the wounds, the lesion treated with the THC-rich Cannabis ointment showed a superior improvement in the healing process compared to the lesion treated only with the placebo. During the 28 days of application, it was possible to notice a significant reduction in the extent of the wound, in the perilesional erythema, and in the production of inflammatory exudate in the surface of Target Lesion B when compared to Target Lesion A, which received the placebo. In addition, there was also a change in the color of the erythematous-violaceous plaque, as the lesion was changing from a dark to a lighter shade, resembling the patient's intact skin (Figure 2).

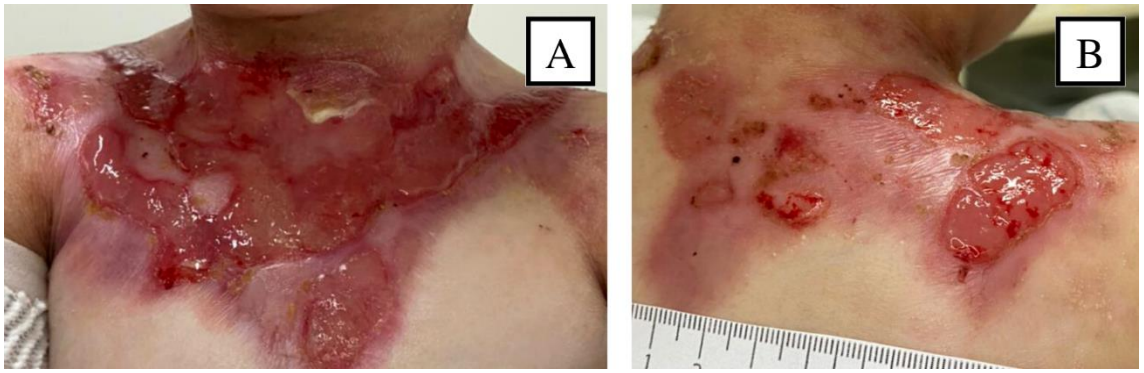


**Figure - 2** Target lesions after 28 days of the beginning of the study. (A) Target lesion A on day 28 of placebo treatment. (B) Target lesion B on day 28 of treatment with THC-rich Cannabis ointment.

Regarding the symptoms of pain and pruritus, her family members and the patient reported that there was a significant reduction in pain already in the first few weeks, which became evident as the patient stopped complaining during baths and dressing changes. In addition, during the 28 days of follow-up, there was a noticeable difference between the symptoms reported in the two lesions. Target lesion A, treated with placebo, had a mean score on the Visual Analog Scale (VAS) of 2.4 for pain and 4.5 for pruritus. Target lesion B, treated with the THC-rich Cannabis ointment had an average score of 0.75 for pain and of 2.4 for pruritus. Thus, it was possible to observe that Target Lesion B presented a 68% improvement in pain and a 46% improvement in pruritus when compared to the pain and pruritus present in Target Lesion A. The VAS

scale ranges from 0 to 10, with 0 being no symptoms and 10 the maximum symptom presented.

In addition, improvement in quality of life and overall well-being was observed after the treatment started. According to her parents' report, the patient was calmer, happier, and more active, returning to school and expressing satisfaction with the treatment. At the end of the 28 days of application of the products, the blinding was removed and due to the marked improvement in the healing process and in the symptoms of pain, pruritus, and overall quality of life, the THC-rich Cannabis ointment began to be also applied to Target Lesion A. Over the course of two months, the THC-rich Cannabis ointment was applied daily to both lesions and no adverse reactions or side effects were observed during this entire follow-up period. Target Lesion A, which was initially treated with placebo, achieved a marked improvement in its healing process, with almost complete reepithelialization (Figure 3).

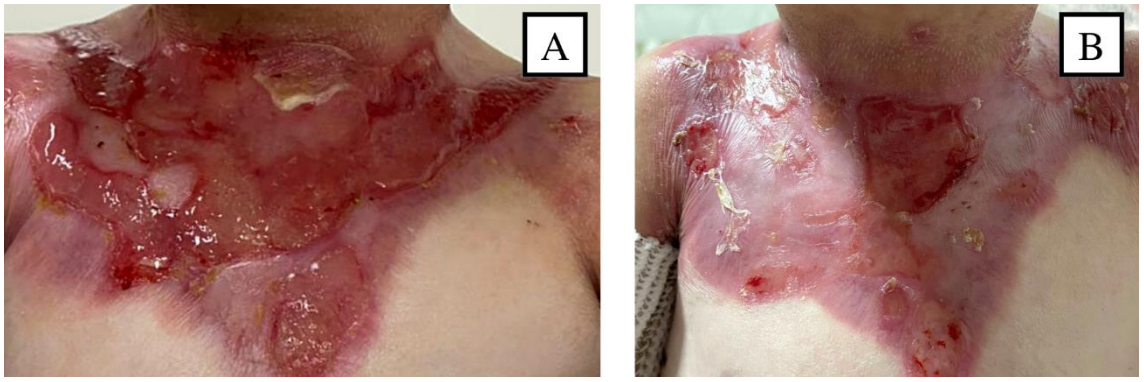


**Figure - 3** Evolution of Target lesion A. (A) Target lesion A before application of the THC-rich Cannabis ointment. (B) Target lesion A after 60 days of using THC-rich Cannabis ointment.

Target lesion B maintained its evolutionary process with complete reepithelialization of the initial lesion and a marked change in the color of the erythematous-violaceous plaque (Figure 4).

ISSN 2965-0771
Revista Brasileira de CANNABIS
SBEC SOCIEDADE BRASILEIRA DE ESTUDOS DA CANNABIS

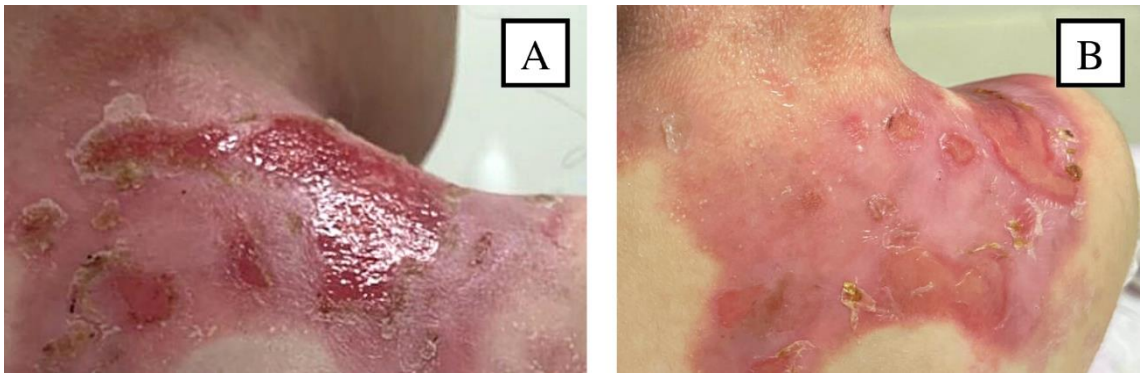


**Figure - 4** Evolution of Target Lesion B. (A) Target lesion B on the initial day of THC-rich Cannabis Ointment treatment. (B) Target lesion B after 70 days of ointment treatment.

## DISCUSSION

Epidermolysis bullosa is a disease that drastically affects the quality of life of patients and their families. In addition to skin fragility, with the formation of blisters at minimal trauma, patients suffer from pain and intense pruritus that is refractory to available therapies. Finally, there is no effective treatment that works in all these areas and that would provide more comfort and quality of life to these patients and their families.

Recent studies have demonstrated great therapeutic potential from cannabinoids, which are the main active substances present in the *Cannabis sativa* plant, for the treatment of numerous diseases, including chronic and inflammatory skin disorders.[9,10] Available data on the use of phytocannabinoids for the treatment of dermatological conditions support a broad spectrum of potentially useful applications. Among the main dermatological effects provided by *Cannabis Sativa*, we have anti-inflammatory action, pruritus control, immunomodulatory effect, analgesic effect, and the induction of apoptosis in cancer cells.[9,12,13]

The mechanisms behind the medicinal effects of *Cannabis sativa* mainly correlate with the binding between phytocannabinoids and CB1 and CB2 receptors, which are membrane receptors coupled to $G_{i/o}$ proteins. The endocannabinoid system, which encompasses these endogenous receptors and ligands, is present in practically the entire body and generally plays a regulatory role. As in other tissues, the regulation of this endogenous system through phytocannabinoids extracted from the *Cannabis sativa* plant appears to be promising for the treatment of various skin diseases.[14] Regarding the anti-inflammatory potential, animal studies have shown a decrease in pro-inflammatory molecules, such as tumor necrosis factor and interleukins (IL-8 and IL-6).[15] Regarding

healing, it is likely that its complex process is influenced by phytocannabinoids, as they have a positive effect on the differentiation and proliferation of keratinocytes, on the action of fibroblasts, and on the control of inflammatory processes in general.[16]

Studies have also shown that the use of *Cannabis sativa* extracts containing all phytocannabinoids has been superior to the use of isolated phytocannabinoids in several diseases.[17,18,19] As an example, a study by Sangiovanni et al. reported the effects of cannabidiol (CBD) and the complete extract of *Cannabis Sativa* on human keratinocytes and human dermal fibroblast cells. In both strains, the treatment with the complete extract down-regulated all inflammation-related genes that were expressed during the study, whereas CBD alone down-regulated only some of these genes. These results indicate that additional components within the complete extract of *Cannabis sativa*, such as other phytocannabinoids, flavonoids, and terpenes may exert a greater synergistic anti-inflammatory effect than CBD alone.[20] This form of combined use of the various substances found in *Cannabis sativa*, known as the entourage effect, improves the effectiveness of the treatment, allows the use of lower doses of cannabinoids, and reduces the number of adverse effects during treatment when compared to the use of molecules isolated from the plant.[17,18,19]

In the reported case, it was noticed that the lesion treated with THC-rich Cannabis ointment evolved much more intensely and faster than the lesion treated only with placebo. In addition, it was noticed that the perilesional erythema involving the lesions was more intense in the lesion treated only with the placebo, suggesting the anti-inflammatory potential of the THC-rich *Cannabis sativa* extract.

After removing the blinding and starting the treatment of Target Lesion A with the THC-rich Cannabis sativa ointment, a significant change in the healing process of this lesion was also observed with significant contraction of the wound edges, demonstrating the potential effect of cannabinoids in the healing process.

Regarding the secondary symptoms of pain and pruritus in the reported case, it was noticed that the lesion treated with THC-rich *Cannabis sativa* ointment obtained much lower scores on the visual analogue scale when compared to the lesion treated only with placebo, suggesting effectiveness of the ointment in decreasing the symptoms of pain and pruritus associated with EB.

Recent evidence suggests benefits of using *Cannabis sativa* for the treatment of chronic pain, acting on both the inflammatory component and the neuropathic pain

component.[13] In addition, the activation of CB1 and CB2 receptors in the skin reduces the sensation of pruritus by causing mast cell hyperpolarization, making it difficult to degranulate pro-inflammatory molecules such as histamine, for example. The activation of these receptors also promotes the hyperpolarization of the cutaneous nerve bundles, decreasing the transmission of stimuli responsible for the pruritus sensation.[9]

## CONCLUSION

It was noticed that the treatment involving the *Cannabis sativa* ointment rich in tetrahydrocannabinol was quite effective in the healing process of chronic wounds, showing improvement in erythema, in the production of inflammatory exudate, and in the overall appearance of the region where the lesions were located.

It was also observed that the topical use of the *Cannabis sativa* ointment was effective in decreasing the symptoms of pain and pruritus, without presenting side effects or adverse effects. In addition, it was noted that the overall quality of life was positively affected after beginning the treatment with the THC-rich Cannabis sativa ointment, with improvement in mood, disposition, and performance of daily activities.

This case report suggests the therapeutic potential of phytocannabinoids for the treatment of EB and the randomized, double-blind, and controlled clinical studies that are underway by the team who carried out this study can consolidate such observations, offering a new perspective of treatment for this disease.

## ACKNOWLEDGEMENT

We would like to thank the NGO ABRACE (*Associação Brasileira de Apoio Cannabis Esperança*) for providing the necessary products to carry out this study and encouraging the conduction of scientific research involving the *Cannabis sativa* plant. We would also like to thank the patient and her guardians for agreeing to participate in this study.

**REFERENCES**

**1.** Laimer M, Prodinger C, Bauer JW. Hereditary epidermolysis bullosa. J Dtsch Dermatol Ges. 2015;**13**:1125–34.

**2.** Azulay RD, Azulay DR.; Azulay-abulafia L. 7th ed. Rio de Janeiro: Gen; 2017.

**3.** Mendes L, Nogueira L, Vilasboas V, Talhari C, Talhari S, Santos M. Kindler syndrome - report of two cases. An Bras Dermatol. 2012;**87**:779-81.

**4.** Has C, Bauer JW, Bodemer C, Bolling MC, Bruckner-Tuderman L, Diem A. Consensus reclassification of inherited epidermolysisbullosa and other disorders with skin fragility. Br J Dermatol. 2020;**183**:614-27.

**5.** Chelliah MP, Zinn Z, Khuu P, Teng JMC. Self-initiated use of topical cannabidiol oil for epidermolysis bullosa. Pediatr Dermatol. 2018;**35**:1–4.

**6.** Jeon IK, On HR, Kim S. Quality of life and economic burden in recessive dystrophic epidermolysis bullosa. Ann Dermatol. 2016;**28**:6–14.

**7.** Schräder NHB, Yuen WY, Jonkman MF. Pain quality assessment scale for epidermolysis bullosa. Acta Derm Venereol. 2018;**98**:346–49.

**8.** Cohn HI, Teng JMC. Advancement in management of epidermolysis bullosa. Curr Opin Pediatr. 2016;**28**:507–16.

**9.** Marks DH, Friedman A. The Therapeutic Potential of Cannabinoids in Dermatology. Skin Therapy Lett. 2018;**23**:1–5.

**10.** Palmieri B, Laurino C, Vadalà M. A therapeutic effect of cbd-enriched ointment in inflammatory skin diseases and cutaneous scars. Clin Ter. 2019;**170**:93–9.

**11.** Schräder NHB, Duipmans JC, Molenbuur B, Wolff AP, Jonkman MF. Combined tetrahydrocannabinol and cannabidiol to treat pain in epidermolysis bullosa: a report of three cases. Br J Dermatol. 2019;**180**:922-24.

**12.** Eagleston LRM, Kalani NK, Patel RR, Flaten HK, Dunnick CA, Dellavalle RP. Cannabinoids in dermatology: a scoping review. Dermatol Online J. 2018;**24**:1–17.

**13.** Romero-Sandoval EA, Kolano AL, Alvarado-Vázquez PA. Cannabis and Cannabinoids for Chronic Pain. Curr Rheumatol Rep. 2017;**19**:67-7.

**14.** Río CD, Millán E, García V, Appendino G, DeMesa J, Muñoz E. The endocannabinoid system of the skin. A potential approach for the treatment of skin disorders. Biochem Pharmacol. 2018;**157**:122–33.

**15.** Klein TW. Cannabinoid-based drugs as anti-inflammatory therapeutics. Nat Rev Immunol. 2005;**5**:400–11.

**16.** Baswan SM, Klosner AE, Glynn K, Rajgopal A, Malik K, Yim S, et al. Therapeutic Potential of Cannabidiol (CBD) for Skin Health and Disorders. Clin Cosmet Investig Dermatol. 2020;**13**:927-42.

**17.** Russo EB. Taming THC: Potential cannabis synergy and phytocannabinoid-terpenoid entourage effects. Br J Pharmacol. 2011;**163**:1344–64.

**18.** Sanchez-ramos J. The entourage effect of the phytocannabinoids. Ann Neurol, 2015;**77**:1083.

**19.** Wilkinson JD, Whalley BJ, Baker D, Pryce G, Constanti A, Gibbons S, et al. Medicinal cannabis: is delta9 -tetrahydrocannabinol necessary for all its effects? J Pharm Pharmacol. 2003;**55**:1687–94.

**20.** Sangiovanni E, Fumagalli M, Pacchetti B, Piazza S, Magnavacca A, Khalilpour S, et al. Cannabis sativa L. Extract and Cannabidiol Inhibit in vitro Mediators of Skin Inflammation and Wound Injury. Phytother Res. 2019;**33**:2083-93.